

<< 6

>>

: 2008 6 27 ( ) 18 ~

:

GSK

: A case of congenital hypoparathyroidism associated with involuntary movement disorder

:

: , ,

D

16

가

5

가

가

가 . Albright  
(perseveration, )

5.4 mg/dL(8.4~10.2),  
< 1 pg/ml

2.4 mg/dL(4.4~5.2),

7.6 mg/dL(2.5~5.5)

. CATCH 22

FISH

(corona radiata)

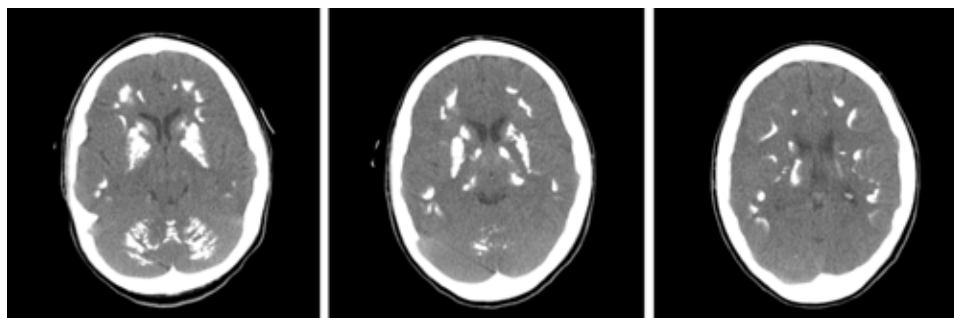
alfacalidol

가

( ).

Fahr

가



**Figure.** Severe intracranial calcifications involving basal ganglia, dentate nucleus and corona radiata revealed by CT.

: NK-T cell adrenal lymphoma diagnosed with delay due to mimicking adrenal hemorrhage  
:  
:

29

CT

, ACTH

MRI

가

CT

fluid collection

,

PET-CT

. PET-CT

CT

MRI

lymphoma

가

hypermetabolism

lymphadenopathy 가

exisional biopsy

non-Hodgkin lymphoma, T cell phenotype

49